

# implants

international magazine of oral implantology

4<sup>2009</sup>

**\_case report**

True Anatomic Immediate Dental Implant Method

**\_case report**

Safe and Effective Alternatives to Sinus Elevation in the Atrophic Posterior Maxilla—Part I

**\_worldwide events**

Complications, Risks, and Failures in Oral Implantology

# True Anatomic Immediate Dental Implant Method

## A Clinical Case

author\_ Wolfgang Pirker, Alfred Kocher, Austria

### Abstract

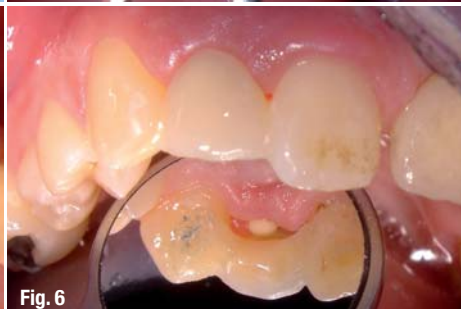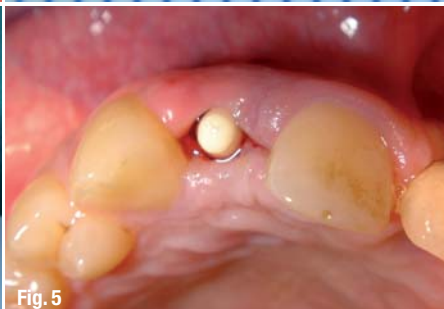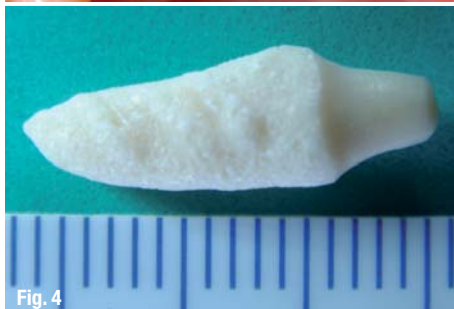
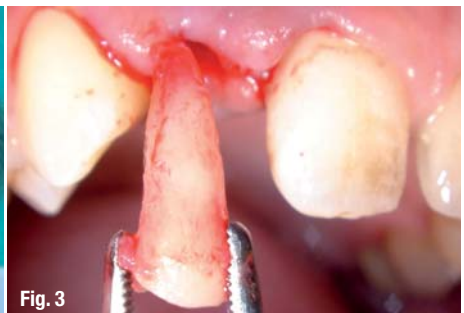
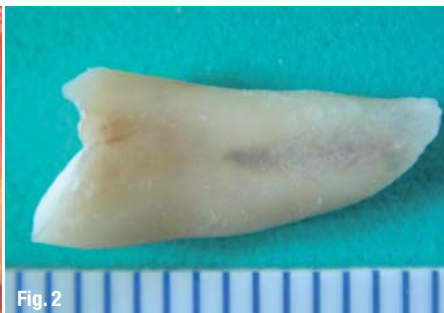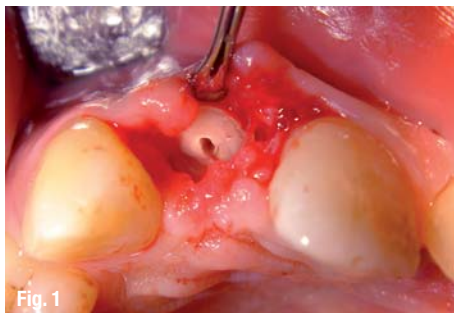
This paper describes a procedure for an immediate, truly root analogue, Zirconia dental implant placed into the extraction socket of a right lateral incisor. The tooth had to be removed because of a root fracture due to a trauma. The custom made root analogue Zirconia implant was roughened by sandblast and modified with macro-retentions in the interdental space. Seven days after extraction the implant was placed into the socket without any alterations of the root socket e.g. drilling or augmentation, by gentle tapping with a hammer and a mallet. Three months after root implantation a composite crown was cemented. No complications occurred during the healing period. An excellent esthetic and functional result was achieved. No clinically noticeable bone resorption or soft-tissue recession was observed at 15 months follow up. Sig-

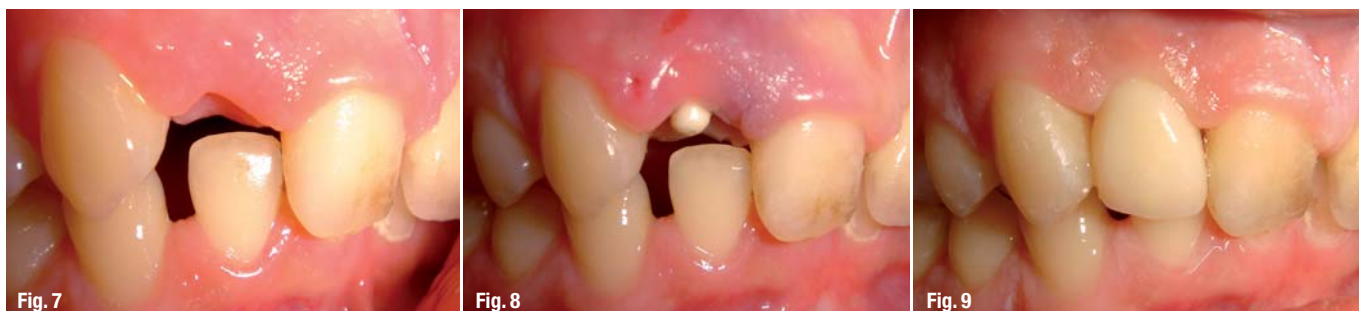nificant modifications such as macroretentions and diameter reduction next to the thin cortical buccal and palatal bone layer seem to indicate that primary stability and excellent osseointegration of immediate root-analogue Zirconia implants can be achieved, while preventing unesthetic bone resorption. This case warrants further clinical research in well controlled trials. For the first time a tooth colored, root identical implant is available and applied successfully in a clinical trial.

### Introduction

Replacement of lost teeth using oral implants is an accepted treatment modality with well documented, high long-term success rates of up to between 90% and 100% at 10-year follow up.<sup>1</sup> More recently immediate implantation within a few days of extraction has

- Fig. 1** Removal of the root.
- Fig. 2** Extracted root.
- Fig. 3** Extracted root next to the extraction socket.
- Fig. 4** True anatomic Zirconia implant with macro-retentions.
- Fig. 5** Root analogue implant in place immediate post operative (occlusal view).
- Fig. 6** Provisional Maryland bridge in place.





been performed clinically in highly selected cases only. However, the indication is nowadays expanding. The major advantages of immediate implant placement are the reduction in treatment time with fewer surgical interventions leading to an improved quality of life and overall cost reduction, and most important socket preservation due to early functional load. Present dental implant strategies that work successfully in delayed implantology have serious limitations regarding functionality and esthetic outcome in immediate implantology.

The main reasons for these shortcomings are based on the fact that currently available dental implants are axially symmetric and made of titanium. In fact, they resemble the natural root neither in form nor in colour. The lack of the correct fit in most instances has to be compensated by multiple complex additional treatments such as bone augmentation, guided tissue regeneration as well as gum plasty. These procedures are time consuming, not fully predictable, generally costly and cause in addition great strain to the patient.

One has to keep in mind that these invasive procedures serve only the purpose to model the bone around a non-fitting titanium implant.

The indication for conventional immediate dental implantation is therefore still strictly limited to a very low percentage of patients with single tooth loss. Furthermore, due to the high sophistication and risk of the procedures the results are extremely dependent on the skills and experience of the surgeon and the compliance of the patient, respectively. Hence, the outcome is hardly predictable and the treatment therefore not suitable for everyday general practice.

On the other hand, a good primary stability and perfect esthetic outcome is simply and safely achieved, by taking advantage of the up to date principles of differentiated osseointegration, the use of Zirconia, a highly biocompatible implant material, combined with the preciseness of the latest CAD/CAM technology. This approach works only in combination with macroretentions in the interdental space and diameter reduction next to the cortical bone.

Compared to conventional implant strategies, the novel, individualized immediate Zirconia dental implant matches the extracted root both in form and color, respects and does not alter the underlying anatomy of the extraction socket and does not require any additional

straining surgical interventions. This most innovative approach is presented herein to a broad expert audience for discussion.

Hodosh and colleagues were the first to use custom-made root-analogue implants placed into the extraction socket, reducing bone and soft-tissue trauma.<sup>2</sup> Experimental studies with root-identical titanium implants yielded extremely favourable results with clear evidence of osseointegration and clinical stability.<sup>3,4</sup> The ensuing clinical trial resulted in 100% primary stability at insertion and 1-month follow-up. Due to the high failure rate of 48% over the short time period of 9 months, this particular implant system was not recommended for clinical use.<sup>5</sup> The present authors selected root-identical implants with significant modifications by 1) using Zirconia for its excellent biocompatibility, plaque-resistance and improved esthetic results; 2) adding micro-retentions to the entire root surface and macro-retentions strictly limited to the interdental space to get beyond primary stability and improve osseointegration; 3) reducing the diameter of the implant next to the thin cortical bone to avoid fracture and pressure-induced bone loss; and 4) choosing a single-stage implantation resulting in immediate, albeit limited, functional load via the crown stump for prevention of bone recession.

### Surgical method

A 27-year-old male patient was referred to our practice for implant treatment of a fracture of the right lateral maxillary incisor (Fig. 1–3). After informed consent was obtained, the root was carefully extracted under local anesthesia (Ultracain DS Forte, Aventis), avoiding any damage to the socket and soft tissue. The extraction socket was cleaned by means of curettage, and an iodoform soaked cotton gaze was placed in the socket. The root was laser scanned and macroretentions were designed strictly limited to the interdental space, sparing the buccal and lingual face, to prevent fractures at the time point of insertion of the thin cortical bone layer. In addition a crown stump was designed for later connection to the crown. The implant was then milled from a zirconium dioxide block (specifically, yttrium-stabilized tetragonal Zirconia polycrystal), and the surface roughened by sandblast and sintered for 8 hours to achieve the desired mechanical properties (Fig. 4). Then the implant was cleaned in an ultrasonic bath contain-

**Fig. 7** Pre operative situs.

**Fig. 8** Root analogue implant in place immediate post operative (buccal view).

**Fig. 9** Final result at 15 months follow-up.

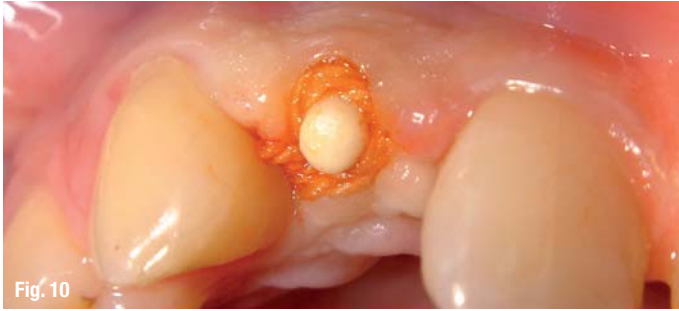

Fig. 10

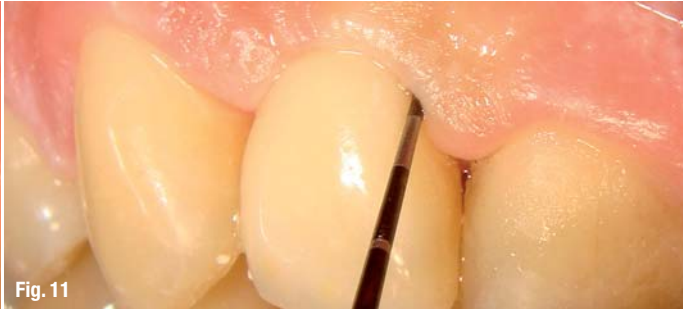

Fig. 11

**Fig. 10\_** Situation before impression with Retraction Cord in place.

**Fig. 11\_** Full restoration at 15 months, no bleeding on probing.

ing 96% ethanol for 10 min, packaged and sterilized in a steam sterilizer. On day 7 the iodoform cotton gaze was removed, and the alveolar socket again curetted and flushed with sterile physiologic saline solution. The custom-made individualized implant was then placed into the socket by gentle tapping with a hammer and a mallet (Fig. 5). Primary stability was achieved as checked by palpation and percussion. The patient received post-operative analgesics (Parkemed 500 mg, Pfizer) on demand and antibiotic medication (Augmentin 625 mg, GlaxoSmithKline) for 4 days. During the healing period the patient received an acrylic Maryland bridge (Fig. 6).

At the control visit 10 days later a clinically healthy marginal area was present, and no postoperative pain or swelling was reported. There was no bleeding or wound infection. After 3 months a composite crown was cemented. At 15 months follow up the patient presented with a stable implant, unchanged peri-implant marginal bone level as monitored by radiographs and soft-tissue parameters, and no bleeding on probing (Figs. 7–14). Hence, as well as an excellent esthetic result there were no signs of periodontitis or bone or soft tissue recession.

**Discussion**

This case report describes the successful dental root replacement with an individualized Zirconia implant in a single patient. The exact technique has been described by our group in an earlier manuscript.<sup>9,10</sup>

Rotationally symmetric titanium implants have stood the test of time for decades in delayed implantation with success rates of up to 98%. But conventional implants were originally constructed for insertion in healed jaw bones, and are primarily not really suited to be inserted into the irregular formed extraction socket. Immediate implantation is—against the suggestion of

some commercials and smaller studies—by no means a standard treatment. It does have a limited indication and requires experienced specialists.

The main reason for the limited indication of immediate single tooth replacement is primarily the lack of bone quantity in the extraction socket, which prohibits adequate bone drilling in the apical region to achieve primary stability requiring a healing period of a submerged implant without any functional load. Scientific literature reports on success rates of immediate implants are similar to delayed implants. However, one has to keep in mind that cases of immediate implantation described in the literature are between 2 to 5% of all implant cases, comprise highly selected patients with limited indications and can therefore not be compared to the standard treatment in the real world.

The natural extraction socket represents the ideal anatomy and starting point for a root formed implant. The anatomic bone situation is ideal for the absorption of the load of a root analogue implant.

On the other hand the fact that the rotationally symmetric implants does not fit at all, leads to a horizontal and vertical atrophy described also as remodeling. In many cases the atrophied bone especially in the presence of thin soft tissue does not appear natural with a grayish gingiva or even visible implant shoulders. These complications may occur within days after implantation or after years in the context of old age involution. A correction of this failure requires a number of invasive procedures with questionable outcome. Old age involution cannot be prevented, therefore it is advisable to use root coloured implants.

The wide array of different available implant forms clearly indicates that osseointegration does not primarily depend on the form of the implant. Aside from

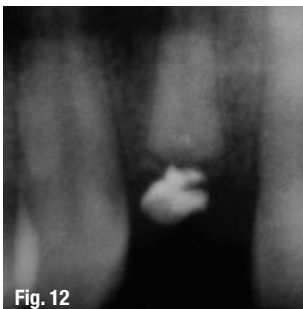


Fig. 12

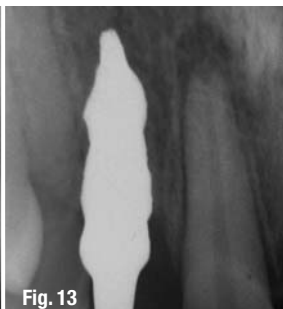

Fig. 13

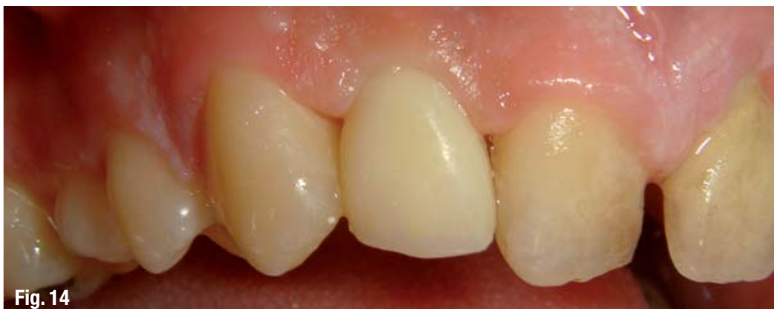

Fig. 14

the surface it is important to prepare the implant site in an atraumatic way and to achieve a perfect bone to implant contact.

There is absolutely no logical reason at all not to use the already existing intact tooth socket as implant site and to adapt the implant to the tooth socket instead of the vice versa approach including drilling, bone trauma, bone loss and additional bone augmentations.

All attempts in the long history of dental science to fix homologue, heterologue or allogeneic root analogue implants into a fresh extraction socket failed due to the conical root form, rejection and lack of preciseness and were therefore not established. With the implementation of the modern CAD/CAM technology it became easily possible to manufacture an exact copy of the dental root.

### “Differentiated Osseointegration”

The fundamental advantage of this innovative implant system is not only the reconstruction of the anatomy of the individual tooth, but also the fact, that it is possible to consider the underlying bone quantity and quality. This way the surface of the implant can be modified accordingly. Macro-retentions (protrusions) are a conditio sine qua non for the safe fixation of a root-formed and therefore conical implant in the bone. Macro-retentions have to be strictly limited to spongy bone, since only spongy bone can absorb pressure without fracture at a remote site. Micro fractures cannot be avoided, but in contrast to fractures of cortical bone fractures in spongy bone remain limited with reduced damage and quick regeneration due to the excellent blood supply always present in spongy bone.

Another reason for the high regenerative potential of spongy bone lies in its extensive vascularization. Retentions in the area of the thin cortical bone leads irrevocably to fractures, sometimes at remote sites, with subsequent bone recession. In order to be on the safe side and avoid fracture of the thin cortical bone at any cost, the implant is reduced at the buccal and lingual face by approximately 0.1–0.2 mm. The principle of differentiated osseointegration therefore dictates the innovative implant design. In areas without macro retentions no fracture or impression induced resorption takes place and primary osseointegration occurs without delay. Only by consideration of these different healing modalities osseointegration can be accomplished in conical or root-analogue formed implants.

### Advantages of the novel method

No bone drilling and drilling guides are necessary. Associated risks are avoided.

No bone drilling equals no operative trauma, no bone loss, no damage to neighboring structures including dental roots, mandible nerve, or maxillary sinus. The exact fit of the implant leads to an optimized

implant-bone contact surface and thus maximal primary stability with shorter healing periods, because there are no gaps between the implant and the bone. Furthermore additional surgical interventions like bone augmentation, guided bone or tissue regeneration are not required. The exclusive use of root colored Zirconia leads reproducibly and predictably to satisfying esthetic results. The single piece implant is exposed to a reduced functional load from the beginning, preventing bone and soft tissue recession. Absolutely no secondary prosthetic parts, no specific surgical instruments, drilling equipments and screw drivers are required. The single stage implant is put in place by use of a mallet and a hammer. Absolute no tool kit is necessary and no special knowledge about the confusing and highly company specific numerous secondary implant parts and their individual names is required. The crown stump can be adapted by means of grinding at any time by use of conventional dental equipment.

### Disadvantages

At the present time patients with damaged periodontal ligament are excluded (careful extraction is mandatory)

- Currently only single stage implants are available.
- Position of misaligned tooth cannot be corrected.
- Method in its infancy, further studies are necessary.
- Dental implant is not yet on the market available.

This case, which is part of a larger ongoing clinical trial, demonstrates that immediate placement of significantly modified, root-analogue, non-submerged Zirconia implants yields excellent results superior to previously described custom made root-analogue titanium implants with a uniform surface.

*The Literature list can be requested from the editorial office.*

_contact	implants
<p><b>Wolfgang Pirker, MD, DDS</b>                      Maxillo-Facial Surgeon                      Schulerstraße 1–3/65                      1010 Vienna, Austria                      Phone: +43-1/5 12-24 00                      E-mail: info@face.at</p>	
<p><b>Alfred Kocher, MD</b>                      Professor of Surgery                      Medical University of Vienna                      Währinger Gürtel 18–20                      1090 Vienna, Austria                      Phone: +43-6 64/2 61 85 69                      Fax: +43-1/5 12-2 25 28                      E-mail: Alfred.Kocher@meduniwien.ac.at</p>	